

## TASK FORCES

# Task Force 1: Preparticipation Screening and Diagnosis of Cardiovascular Disease in Athletes

Barry J. Maron, MD, FACC, *Chair*

Pamela S. Douglas, MD, FACC, Thomas P. Graham, MD, FACC, Rick A. Nishimura, MD, FACC,  
Paul D. Thompson, MD, FACC

The present consensus panel recommendations of the 36th Bethesda Conference for eligibility and disqualification of competitive athletes are predicated on the prior diagnosis of cardiovascular abnormalities. However, the methodology by which these diseases are identified (including preparticipation screening) and how athletes come to evaluation for competitive eligibility, may involve several scenarios. First, athletes may be referred for assessment of clinical symptoms or signs. Second, fortuitous recognition may occur in routine clinical practice, triggered by findings on history and physical examination, such as a heart murmur. Third, young athletes may be suspected of having cardiovascular disease by virtue of formalized large population screening examinations that are customary before participation in competitive athletics (1).

## PREPARTICIPATION SCREENING

Indeed, the ultimate objective of preparticipation screening carried out in general populations of trained athletes is the recognition of “silent” cardiovascular abnormalities that can progress or cause sudden cardiac death. Such screening efforts have the capability of raising the clinical suspicion of several cardiovascular diseases—usually by virtue of a heart murmur, regarded to be of potential clinical significance, cardiac symptoms (e.g., exertional chest pain, disproportionate dyspnea, or impairment in consciousness), or a family history of heart disease or sudden unexpected death. However, a major obstacle to implementation of large-scale screening in the U.S. is the substantial number of young athletes eligible for evaluation (about 10 to 12 million) and the rarity of the cardiac diseases capable of causing sudden death in this population (estimated prevalence, less than or equal to 0.3%) (2).

Customary screening strategies for U.S. high school and college athletes is confined to history-taking and physical examination, generally acknowledged to be limited in its power to consistently identify important cardiovascular abnormalities. In one retrospective study, only 3% of trained athletes who died suddenly of heart disease (and had been exposed to preparticipation screening) were suspected of harboring cardiovascular disease on the basis of history and physical examination—and none had been disqualified from competition (3). Although most trained athletes with occult cardiovascular disease are asymptomatic, the prior history of

exertional-related syncope in a young athlete unavoidably raises the consideration of a number of diseases known to cause sudden cardiac death, including hypertrophic cardiomyopathy (HCM) and ion-channel disorders, but in particular should also heighten the level of clinical suspicion for congenital coronary anomalies of wrong sinus origin (4).

Furthermore, the quality of cardiovascular screening for U.S. high school and college athletes, particularly the design of approved questionnaires, has come under scrutiny regarding inadequacies (5,6) when measured against American Heart Association (AHA) recommendations (1) (Table 1). Legislation in several states allows health care workers with vastly different levels of training and expertise (including chiropractors and naturopathic clinicians) to conduct preparticipation sports examinations, often under suboptimal conditions. Improvement in this screening process, including the training level of examiners, would undoubtedly result in a greater number of athletes identified with previously unsuspected but clinically relevant cardiovascular abnormalities. Indeed, development and dissemination of a standardized and uniform national preparticipation history and physical examination form for medical screening in all high schools and colleges (which incorporates the AHA recommendations) would be the most practical approach for achieving this goal.

Certainly, the diagnosis of genetic diseases, such as HCM, arrhythmogenic right ventricular cardiomyopathy (ARVC), long QT and Brugada syndromes, and other inherited arrhythmia syndromes in asymptomatic patients has now taken on even greater relevance. This is because individuals judged to be at sufficiently high-risk may be eligible for primary prevention of sudden cardiac death with an implantable cardioverter-defibrillator (7,8).

Conversely, in Italy, for the past 25 years, a formal national preparticipation screening and medical clearance program has been mandated for young competitive athletes in organized sports programs (9,10). The Italian system is unique by virtue of requiring annual evaluations that routinely include a 12-lead electrocardiogram (ECG) as well as a history and physical examination; the ECG itself has proven most useful in the identification of many previously undiagnosed athletes with HCM (10). However, such screening efforts may be complicated by the substantial proportion of false-positive test results that potentially represent a major burden to athletes, their families, and the

**Table 1.** AHA Consensus Panel Recommendations for Preparticipation Athletic Screening (1)

---

Family History
1. Premature sudden cardiac death
2. Heart disease in surviving relatives less than 50 years old
Personal History
3. Heart murmur
4. Systemic hypertension
5. Fatigue
6. Syncope/near-syncope
7. Excessive/unexplained exertional dyspnea
8. Exertional chest pain
Physical Examination
9. Heart murmur (supine/standing*)
10. Femoral arterial pulses (to exclude coarctation of aorta)
11. Stigmata of Marfan syndrome
12. Brachial blood pressure measurement (sitting)

---

\*In particular, to identify heart murmur consistent with dynamic obstruction to left ventricular outflow. From Maron BJ, et al. *Circulation* 1996;94:850-6, reprinted with permission of the American Heart Association.

testing facilities. Obstacles in the U.S. to implementing obligatory government-sponsored national screening including ECGs or echocardiograms are the particularly large population of athletes to screen, major cost-benefit considerations, and the recognition that it is impossible to absolutely eliminate the risks associated with competitive sports (1,2). Nevertheless, some volunteer-based small-scale screening programs using portable echocardiograms to examine high-school athletes on the field for HCM have emerged.

Systematic preparticipation cardiovascular screening, primarily to exclude atherosclerotic coronary artery disease in older athletes, is not customary practice. Such persons are largely participants in individual athletic activities such as road and marathon racing, or in a variety of other organized master's sports (11).

## DIAGNOSTIC TESTING STRATEGIES

When a cardiovascular abnormality is initially suspected (by formal screening or otherwise), the diagnostic strategy should focus on the systematic exclusion of those conditions known to cause sudden death in young athletes; these approaches include echocardiography, ECG, history, and physical examination. Additional noninvasive (and invasive) testing with cardiac magnetic resonance imaging (CMR), exercise testing, ambulatory Holter ECG recording, implanted loop recorder, tilt table examination, or electrophysiologic testing with programmed stimulation can be considered in selected patients. Diagnostic myocardial biopsies are used only selectively in athletes suspected clinically of myocarditis.

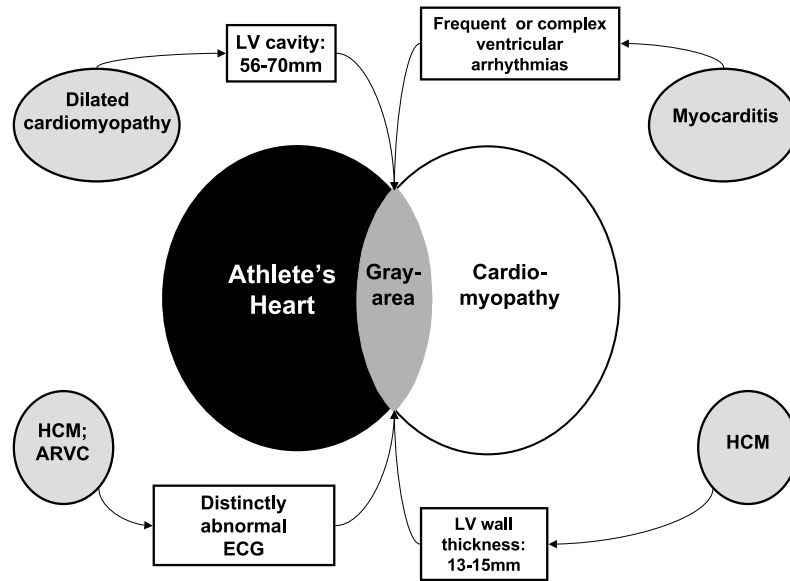
Despite considerable assembled data regarding DNA-based diagnosis over the past decade, identification of genetic cardiovascular diseases such as HCM, long QT syndrome, and other ion-channel disorders, ARVC, and Marfan syndrome continues to be made through clinical testing in the vast majority of cases, and this will remain so

in the foreseeable future. At present, genetic testing is not easily available on a routine clinical basis for most genetic heart diseases, or for application to large athletic populations given the expensive and complex methodologies involved and the genetic heterogeneity characteristic of these diseases (12).

**Echocardiography.** Two-dimensional echocardiography is the principal diagnostic imaging modality for clinical identification of HCM by demonstrating otherwise unexplained and usually asymmetric left ventricular (LV) wall thickening (12,13). In this regard, a maximal LV end-diastolic wall thickness of 15 mm or more (or on occasion, 13 or 14 mm) is the absolute dimension generally accepted for the clinical diagnosis of HCM in an adult athlete (two or more standard deviations from the mean relative to body surface area; z-score of two or more in children) (12,13); however, any specific LV wall thickness (including normal) is theoretically compatible with the presence of a mutant HCM gene (12,14). Echocardiography would also be expected to detect and define other specific and relevant congenital structural abnormalities associated with sudden death or disease progression in young athletes such as valvular heart disease (e.g., mitral valve prolapse and aortic valve stenosis), aortic root dilatation and mitral valve prolapse in Marfan or related syndromes, and LV dysfunction and/or enlargement (evident in myocarditis and dilated cardiomyopathy). Such diagnostic testing requires interpretation by physicians trained in echocardiography, but cannot guarantee full recognition of all relevant lesions, and some important diseases may escape detection despite expert screening methodology. For example, the HCM phenotype may not be evident when echocardiography is performed in the pre-hypertrophic phase (i.e., a patient less than 14 years of age) (12). Annual serial echocardiography is recommended in HCM family members throughout adolescence (12,14).

**Electrocardiography.** The 12-lead ECG may be of use in the diagnosis of cardiovascular disease in young athletes, and has been promoted as a practical and cost-effective strategic alternative to routine echocardiography for population-based preparticipation screening. For example, the ECG is abnormal in up to 75% to 95% of patients with HCM, and often before the appearance of hypertrophy (12). The ECG will also identify many individuals with the long QT, Brugada, and other inherited syndromes associated with ventricular arrhythmias. It raises the suspicion of myocarditis by premature ventricular complexes and ST-T abnormalities, or ARVC by T-wave inversion in leads V<sub>1</sub> through V<sub>3</sub> and low amplitude potentials (epsilon waves) (1,2). Of note, however, a not inconsequential proportion of genetically affected family members with long QT syndrome may not express QT interval prolongation, and ECG abnormalities are usually absent in random recordings from patients with congenital coronary artery anomalies (4).

**Other tests.** In those cases in which the echocardiogram is normal or borderline for LV hypertrophy, but a suspicion



**Figure 1.** Gray area of overlap between athlete's heart and cardiomyopathies, including myocarditis, hypertrophic cardiomyopathy (HCM), and arrhythmogenic right ventricular cardiomyopathy (ARVC). ECG = electrocardiogram; LV = left ventricular. From Maron BJ, *N Engl J Med* 2003;349:1064-75, with permission of Massachusetts Medical Society (2).

for HCM persists (often due to an abnormal 12-lead ECG), CMR may be useful in clarifying wall thickness or detecting segmental areas of hypertrophy in selected regions of the LV chamber which may be more difficult to image reliably with conventional echocardiography, such as anterolateral free wall or apex (15,16).

Definitive identification of congenital coronary artery anomalies of wrong sinus origin usually requires sophisticated laboratory imaging, including multi-slice computed tomography or coronary arteriography. However, in young athletes it is possible to raise the suspicion of these malformations with transthoracic or transesophageal echocardiography or CMR imaging. Often, ARVC cannot be diagnosed reliably with echocardiography, and CMR is probably the most useful noninvasive test for identifying the structural abnormalities in this condition (i.e., right ventricular enlargement, wall motion abnormalities, adipose tissue replacement within the wall, and aneurysm formation); however, CMR is not an entirely sensitive or specific diagnostic modality in ARVC (17).

### ATHLETE'S HEART AND CARDIOVASCULAR DISEASE

Systematic training in endurance or isometric sports may trigger physiologic adaptations and structural cardiac remodeling, including increased LV wall thickness, enlarged ventricular and atrial cavity dimensions, and calculated cardiac mass, in the presence of normal systolic and diastolic function (i.e., athlete's heart) (18). The magnitude of physiologic hypertrophy may also vary according to the particular type of sports training. Other adaptations to training include a variety of abnormal 12-lead ECG patterns in about 40% of elite athletes, which not infrequently

mimic those of cardiac disease (i.e., increased R- or S-wave voltages, Q waves, and repolarization abnormalities) (19). Frequent and/or complex ventricular tachyarrhythmias on ambulatory (Holter) ECG are not uncommonly found in athletes and can also mimic certain cardiac diseases, including myocarditis (20).

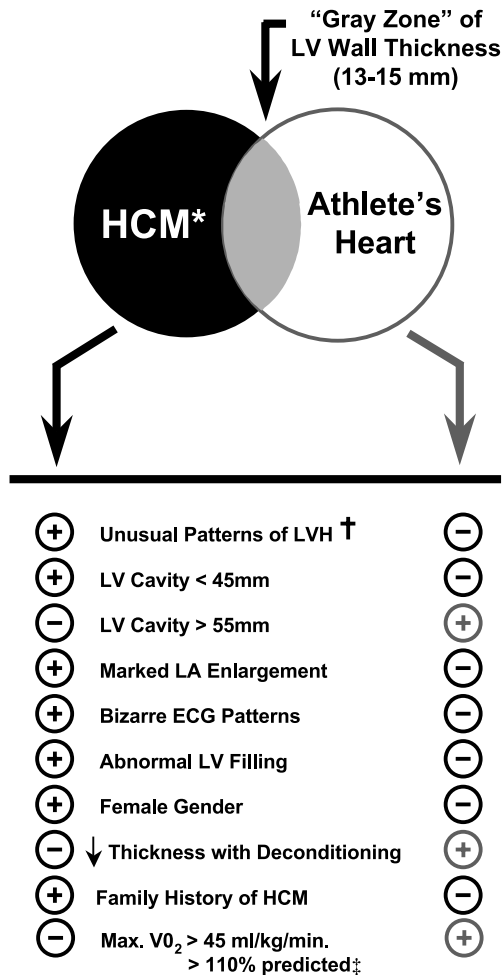
Clinical distinctions between physiologic athlete's heart and pathologic conditions (18-23) have critical implications for trained athletes, because cardiovascular abnormalities may trigger disqualification from competitive sports to reduce the risk of sudden death or disease progression. An over-diagnosis may lead to unnecessary restrictions, depriving athletes of the psychological, social, or possibly (in some elite athletes) economic benefits of sports (2).

Morphologic adaptations of athlete's heart can closely resemble certain cardiovascular diseases and lead to a differential diagnosis with HCM, dilated cardiomyopathy, and ARVC (2) (Fig. 1). Such clinical dilemmas not infrequently arise when cardiac dimensions fall outside clinically accepted partition values. For example, 2% of highly trained adult male athletes show relatively mild increases in LV wall thickness (13 to 15 mm) and 15% have LV cavity enlargement greater than or equal to 60 mm (2,21,22); both fall into a borderline and inconclusive "gray zone" for which extreme expressions of benign athlete's heart and mild morphologic forms of cardiomyopathy overlap (2,22,23). Indeed, the two most common clinical scenarios encountered that unavoidably generate ambiguous diagnoses in trained athletes are: 1) differentiating HCM from athlete's heart in athletes with an LV wall thickness of 13 to 15 mm, non-dilated and normally contractile LV, and absence of mitral valve systolic anterior motion; and 2) differentiating

**Task Force 1: Preparticipation Screening and Diagnosis**

CMR imaging, genotyping, and serial acquisition of clinical and morphologic evidence over time.

doi:10.1016/j.jacc.2005.02.007



**Figure 2.** Chart showing criteria used to favor or distinguish hypertrophic cardiomyopathy (HCM) from athlete's heart when maximal left ventricular (LV) wall thickness is within shaded gray zone of overlap (i.e., 13 to 15 mm), consistent with both diagnoses. \*Assumed to be the non-obstructive form of HCM (under resting conditions) in this discussion because the presence of substantial mitral valve systolic anterior motion would confirm the diagnosis of HCM in the athlete. †May involve a variety of abnormalities, including heterogeneous distribution of left ventricular hypertrophy (LVH) in which asymmetry is prominent and adjacent regions may show greatly different thicknesses with sharp transitions evident between segments, as well as unusual patterns in which the anterior ventricular septum is spared from the hypertrophic process and LV thickening may be in posterior portion of septum or anterolateral or posterior free wall or apex. ‡Assessed with cardiopulmonary (metabolic) exercise testing. ↓ = decreased; ECG = electrocardiogram; LA = left atrial. From Maron BJ, et al. *Circulation* 1995;91:1596-601, reprinted with permission of the American Heart Association (22).

early presentation of dilated cardiomyopathy from athlete's heart with LV end-diastolic cavity dimension 60 mm or more with low-normal LV function (i.e., ejection fraction of 50% to 55%).

Such cases with diagnostic uncertainty are not uncommon and may be resolved in many athletes by a number of independent noninvasive clinical parameters, including the response of cardiac mass to short periods of deconditioning, or assessment of diastolic filling (22) (Fig. 2). Clarification of such diagnostic ambiguities may also be achieved with

**TASK FORCE 1 REFERENCES**

1. Maron BJ, Thompson PD, Puffer JC, et al. Cardiovascular preparticipation screening of competitive athletes: a statement for health professionals from the Sudden Death Committee (clinical cardiology) and Congenital Cardiac Defects Committee (cardiovascular disease in the young), American Heart Association. *Circulation* 1996;94:850-6.
2. Maron BJ. Sudden death in young athletes. *N Engl J Med* 2003;349:1064-75.
3. Maron BJ, Shirani J, Poliac LC, Mathenge R, Roberts WC, Mueller FO. Sudden death in young competitive athletes: clinical, demographic, and pathological profiles. *JAMA* 1996;276:199-204.
4. Basso C, Maron BJ, Corrado D, Thiene G. Clinical profile of congenital coronary artery anomalies with origin from the wrong aortic sinus leading to sudden death in young competitive athletes. *J Am Coll Cardiol* 2000;35:1493-501.
5. Glover DW, Maron BJ. Profile of preparticipation cardiovascular screening for high school athletes. *JAMA* 1998;279:1817-9.
6. Pfister GC, Puffer JC, Maron BJ. Preparticipation cardiovascular screening for U.S. collegiate student-athletes. *JAMA* 2000;283:1597-9.
7. Maron BJ, Shen WK, Link MS, et al. Efficacy of implantable cardioverter-defibrillators for the prevention of sudden death in patients with hypertrophic cardiomyopathy. *N Engl J Med* 2000;342:365-73.
8. Corrado D, Leoni L, Link MS, et al. Implantable cardioverter-defibrillator therapy for prevention of sudden death in patients with arrhythmogenic right ventricular cardiomyopathy/dysplasia. *Circulation* 2003;108:3084-91.
9. Pelliccia A, Maron BJ. Preparticipation cardiovascular evaluation of the competitive athlete: perspectives from the 30-year Italian experience. *Am J Cardiol* 1995;75:827-9.
10. Corrado D, Basso C, Schiavon M, Thiene G. Screening for hypertrophic cardiomyopathy in young athletes. *N Engl J Med* 1998;339:364-9.
11. Maron BJ, Araújo CG, Thompson PD, et al. Recommendations for preparticipation screening and the assessment of cardiovascular disease in Master's athletes: an advisory for healthcare professionals from the working groups of the World Heart Federation, the International Federation of Sports Medicine, and the American Heart Association Committee on Exercise, Cardiac Rehabilitation, and Prevention. *Circulation* 2001;103:327-34.
12. Maron BJ, McKenna WJ, Danielson GK, et al. American College of Cardiology/European Society of Cardiology clinical expert consensus document on hypertrophic cardiomyopathy: a report of the American College of Cardiology Foundation Task Force on Clinical Expert Consensus Documents and the European Society of Cardiology Committee for Practice Guidelines. *J Am Coll Cardiol* 2003;42:1687-713.
13. Klues HG, Schiffers A, Maron BJ. Phenotypic spectrum and patterns of left ventricular hypertrophy in hypertrophic cardiomyopathy: morphologic observations and significance as assessed by two-dimensional echocardiography in 600 patients. *J Am Coll Cardiol* 1995;26:1699-708.
14. Maron BJ, Seidman JG, Seidman CE. Proposal for contemporary screening strategies in families with hypertrophic cardiomyopathy. *J Am Coll Cardiol* 2004;44:2125-32.
15. Rickers C, Wilke NM, Jerosch-Herold M, et al. Utility of cardiac magnetic resonance imaging in the diagnosis of hypertrophic cardiomyopathy. *Circulation* 2005. In press.
16. Moon JCC, Fisher NG, McKenna WJ, Pennell DJ. Detection of apical hypertrophic cardiomyopathy by cardiovascular magnetic resonance in patients with non-diagnostic echocardiography. *Heart* 2004;90:645-49.
17. Tandri H, Calkins H, Nasir K, et al. Magnetic resonance imaging findings in patients meeting task force criteria for arrhythmogenic right ventricular dysplasia. *J Cardiovasc Electrophysiol* 2003;14:476-82.

18. Pluim BM, Zwinderman AH, van der Laarse A, van der Wall EE. The athlete's heart: a meta-analysis of cardiac structure and function. *Circulation* 2000;101:336–44.
19. Pelliccia A, Maron BJ, Culasso F, et al. Clinical significance of abnormal electrocardiographic patterns in trained athletes. *Circulation* 2000;102:278–84.
20. Biffi A, Pelliccia A, Verdile L, et al. Long-term clinical significance of frequent and complex ventricular tachyarrhythmias in trained athletes. *J Am Coll Cardiol* 2002;40:446–52.
21. Pelliccia A, Maron BJ, Spataro A, Proschan MA, Spirito P. The upper limit of physiologic cardiac hypertrophy in highly trained elite athletes. *N Engl J Med* 1991;324:295–301.
22. Maron BJ, Pelliccia A, Spirito P. Cardiac disease in young trained athletes: insights into methods for distinguishing athlete's heart from structural heart disease, with particular emphasis on hypertrophic cardiomyopathy. *Circulation* 1995;91:1596–601.
23. Pelliccia A, Culasso F, Di Paolo FM, Maron BJ. Physiologic left ventricular cavity dilatation in elite athletes. *Ann Intern Med* 1999;130:23–31.

**Appendix 1. Author Relationships With Industry and Others**

Name	Consultant	Research Grant	Speaker's Bureau	Stock Holder	Expert Witness Testimony
Dr. Barry J. Maron	None	• Medtronic	None	None	• 1996, Defense, Northwestern vs. Knapp
Dr. Pamela S. Douglas	None	None	None	None	None
Dr. Rick A. Nishimura	None	None	None	None	None
Dr. Thomas P. Graham	None	None	None	None	None
Dr. Paul D. Thompson	<ul style="list-style-type: none"> <li>• Astra Zeneca</li> <li>• Bristol Myers Squibb</li> </ul>	<ul style="list-style-type: none"> <li>• Astra Zeneca</li> <li>• Merck</li> <li>• Pfizer</li> <li>• Schering</li> </ul>	<ul style="list-style-type: none"> <li>• Astra Zeneca</li> <li>• Merck</li> <li>• Pfizer</li> <li>• Schering</li> </ul>	<ul style="list-style-type: none"> <li>• Pfizer</li> <li>• Schering</li> </ul>	<ul style="list-style-type: none"> <li>• 2005, Plaintiff, Sudden death in college athlete</li> <li>• 2004, Defense, Stress test/recreational sports</li> <li>• 2002, Sudden death, World Gym</li> <li>• 2002, Plaintiff, Sudden death, truck driver</li> <li>• 1998, Plaintiff, Sudden death, recreational sports</li> </ul>

## Task Force 2: Congenital Heart Disease

Thomas P. Graham, JR, MD, FACC, *Chair*

David J. Driscoll, MD, FACC, Welton M. Gersony, MD, FACC,

Jane W. Newburger, MD, MPH, FACC, Albert Rocchini, MD, Jeffrey A. Towbin, MD, FACC

### GENERAL CONSIDERATIONS

The most common congenital heart lesions that have been associated with sudden death during sports participation are hypertrophic cardiomyopathy, coronary artery anomalies, Marfan syndrome, and aortic valve disease (1–3). Less common lesions include complex defects, such as transposition and single ventricle, and those with associated pulmonary vascular disease.

The recommendations presented are intended to provide broad guidelines for patients with congenital heart defects (4). When questions about the safety of sports participation arise, there is no substitute for a comprehensive evaluation by a knowledgeable and experienced physician. Exercise testing can be useful, particularly if symptoms, the electrocardiogram (ECG), and blood pressure are monitored during conditions that simulate the sport in question. Arrhythmias discussed in this Task Force are usually identified by exercise testing or some form of long-term monitoring (including ambulatory Holter and event recording). Serial evaluations may be required because of changing hemodynamic status with time.

### TYPES OF CONGENITAL DEFECTS

**Atrial septal defect (ASD)—untreated.** Most children with ASD are asymptomatic, and closure is usually carried out before they are active in competitive sports. An ECG and echocardiogram are required for evaluation. Small atrial defects are characterized by minimal or no right ventricular volume overload, moderate or large defects have significant volume overload but pulmonary hypertension is unusual.

*Recommendations:*

1. **Athletes with small defects, normal right heart volume, and no pulmonary hypertension can participate in all sports.**
2. **Athletes with a large ASD and normal pulmonary artery pressure can participate in all competitive sports.**
3. **Athletes with an ASD and mild pulmonary hypertension can participate in low-intensity competitive sports (class IA). Patients with associated pulmonary vascular obstructive disease who have cyanosis and a large right-to-left shunt cannot participate in competitive sports.**